

1. What is EOTRH?

“EOTRH” or “Equine Odontoclastic Tooth Resorption and Hypercementosis” is a disease affecting the teeth of horses. It is most commonly diagnosed in older horses over 15 years of age and affects mainly the incisors and canine teeth. It describes a repetitive process where the affected teeth are being eaten away by the body’s own cells (odontoclasts), and in an effort to repair, may then lay down excess tooth material called cementum (hypercementosis).

2. Why does it happen?

There are a few theories about why EOTRH happens, and there is a general consensus that biomechanical forces on the periodontal ligaments that attach the teeth to the bone are increased in older teeth due to their shape, and there is likely secondary involvement of micro-organisms (bacteria) that contributes to the disease progression.¹

3. How do we diagnose EOTRH?

EOTRH is definitively diagnosed on X-rays, usually taken when the external appearance of the teeth is indicative of the condition (gingival recession, swelling, and periodontal disease are common signs) or description of abnormal oral behaviours (such as difficulty chewing, bad breath, biting problems, head shaking) by the owner indicates that there may be presence of the disease.¹ EOTRH is a very painful condition due to the destruction of the structures surrounding the tooth as well as potentially the nerve supply to the tooth itself.

4. What treatment options are there for EOTRH?

Unfortunately, at this time there are no known treatments to stop the progression of the disease and repair the damaged teeth. The only known and accepted treatment is removal of the affected teeth when the destruction and pain associated begins to clinically affect the horse (severe changes present on x-rays +/- the presence of clinical signs (e.g. difficulty biting down on a carrot.)

5. What will my horse be like if we remove the affected teeth?

Horses can still graze, drink, eat hay (though small-holed haynets are a challenge) and function completely normally. Most owners report the horse has a better demeanour, appears more comfortable, and gain weight after the surgery. Many horses still continue to perform in their ridden careers too. The most noticeable difference after the surgery is that if all incisors are removed, the tongue will poke out of your horse’s mouth. This is of no consequence to them and is purely cosmetic (and frankly quite adorable.)

How can I check if my horse is in pain due to EOTRH?

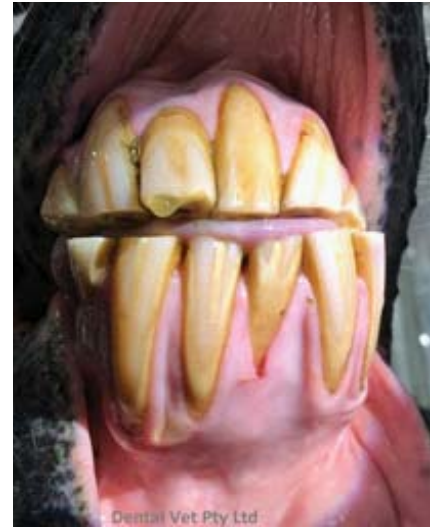The “carrot test” is a good way to check whether your horse is comfortable or whether he might have pain in his incisors due to EOTRH.

If he is quite comfortable to bite down (chomp all the way through) a carrot, it’s less likely he is in pain.

If he holds it between his teeth but tries to get you to snap it, or moves his head around but won’t chomp, his incisors may be painful!

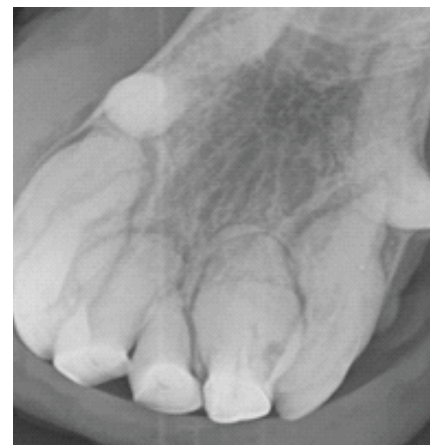
References:

1. Hole, S. and Staszuk, C. (2016). Equine odontoclastic tooth resorption and hypercementosis. Equine Veterinary Education, 30(7), pp.386-391



Above: Abnormal appearing incisors in a horse with EOTRH

Below: X-ray findings in a horse with EOTRH, including osteoclastic lesions (a) and hypercementosis (b)



Copyright © 2014-2020 Funny Horse Cartoons