

# Peripheral Caries



## What is peripheral caries?

Peripheral caries refers to caries (decay) of the outsides of the teeth. It is caused by acidic pH in the mouth leading to a chemical reaction that results in demineralisation, or 'decay' of the teeth. It starts on the peripheral cementum (outermost layer of the teeth), and if the duration of acidity within the mouth is prolonged, it can progress to the inner structures of the teeth, including the enamel and dentin. In the more severe cases, peripheral caries may lead to dental fractures, exposure of the vital cavities of the teeth (which can kill the teeth), soft tissue lacerations and periodontal disease among other complications.

## Why does it happen?

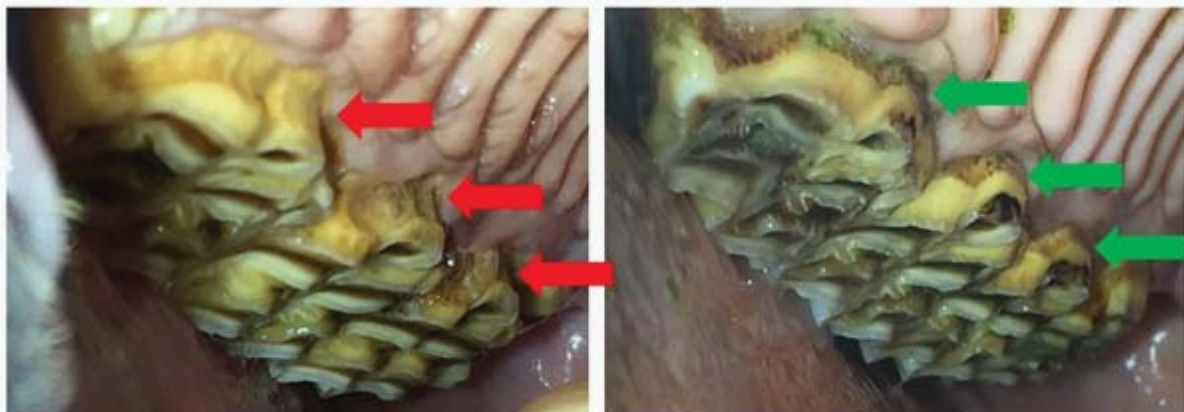
The disease appears to be multifactorial. Research has shown that horses fed certain hays containing a high percentage of water-soluble carbohydrates (WSC) such as oaten hay, are more likely to be affected by the condition. Certain carbohydrates are easily fermented by oral bacteria, which release organic acids as a by-product of this fermentation and these acids dissolve the minerals in the teeth. Water with an acidic pH (e.g. Perth rainwater) is likely to contribute to development of peripheral caries, whereas slightly alkaline water may be protective. Access to good-quality pasture throughout the year may also be protective.<sup>1</sup>

## How do we diagnose peripheral caries?

Peripheral caries is diagnosed by visual examination of decay of the outer structures of the horse's teeth by your veterinarian. The severity is graded depending on the degree and distribution of decay, and ranges from 1.1 (minor decay of the outer cemental layer of the teeth) to 4 (decay resulting in fracture of the teeth/loss of normal tooth architecture).

## What treatment options are there for peripheral caries?

The good news is the condition only affects the part of the tooth in the mouth at the time- the tooth below the gumline is unaffected. As horses teeth continue to erupt throughout their lifetime, the condition can be 'cured' in many cases if the causal agent is removed from the diet, as the damaged tooth is replaced over time by the eruption of the unaffected part of the tooth that was below the gum. As such, it is recommended that horses on high WSC hays should be changed to an alternative hay source with lower WSC (such as Meadow, Rhodes, Barley straw or Lucerne hay). In cases where the water source may be contributing, the pH may be tested and alkalising agents potentially added to the trough. Fluoride varnish may be applied to the decayed teeth to form a protective substance called fluoroapatite, which may help prevent further decay of the teeth for up to 6 months following treatment. Periodontal disease, which occurs commonly with peripheral caries, should also be treated concurrently.<sup>2</sup>



Equine peripheral caries shown before (left) and after (right) dietary change from high-WSC oaten hay to low-WSC Rhodes hay and barley straw showing the new, healthy outer layer of cementum erupting down. Photos taken 7 months apart.

### References:

1. Jackson, K., Kelty, E. and Tennant, M. (2017). Equine peripheral dental caries: An epidemiological survey assessing prevalence and possible risk factors in Western Australian horses. *Equine Veterinary Journal*, 50(1), pp.79-84.
2. Jackson, K., Kelty, E., Staszuk, C. and Tennant, M. (2019). Peripheral caries and disease of the periodontium in Western Australian horses: An epidemiological, anatomical and histopathological assessment. *Equine Veterinary Journal*, 51(5), pp.617-624.